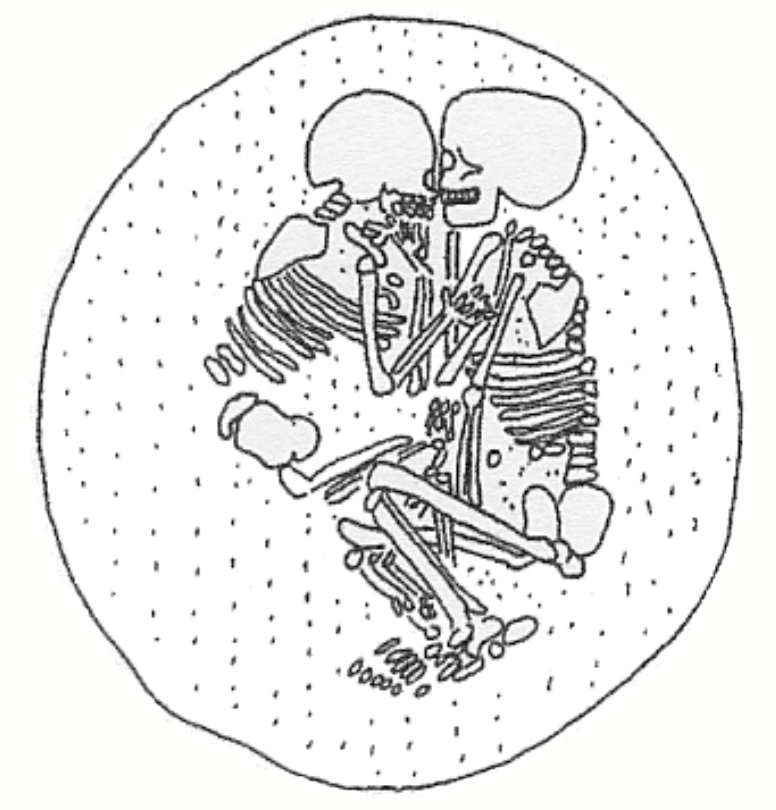

An exceptional late Slavic elite burial at Stolpe on the Oder

Susanne Storch¹, Dr. Felix Biermann², Dr. Thomas Kersting³, Philipp Roskoschinski⁴

Introduction

In the autumn 2012 a late Slavic elite burial from the first half of the 12th Century was discovered and excavated in Stolpe, on the Oder (Uckermark) in the foreland of the famous stronghold (Fig. 9). The BLDAM and the University of Göttingen carried out the emergency excavation.

The grave was equipped with a sword, an unusual belt buckle and a ferrous metal bowl (Fig. 1). They join the grave in a group of chief funerals of the 11./12. century in Pomerania, North of Brandenburg and Mecklenburg. At this time the North-West Slavic area was covered by permanent military conflicts between the Lutizen and the German, Danish and Polish Kingdoms, as well as religious conflicts (Christianization) and political instability. We have known about these political and religious upheavals mainly from historical sources. Thus, the elite Slavic burial is one of the few finding, demonstrating the use of force not only in burial objects, but also manifested by the buried person.

Material and Methods

The investigation of the skeleton was made macroscopically. The bones had a very good to moderate consistency. The body laid almost entirely in an anatomical correct position. The left upper limb could not be studied because it was excavated as a block together with the sword. The analysis focused on the age, sex, body height, pathologies, anatomic variations and enthesopathies. The determination of age and sex carried out by the conventional methods of Ferembach et al. (1979). In addition, the transition analysis by Milner / Boldsen (2002) was used for age estimation. The body height was calculated using the formula of Pearson (1899), pathologies were judged according to the criteria of Schultz (1988).

Results

The skeleton from grave 1 is an late-adult to late-mature man, who died between 35 and 60 years of age. The transition analysis resulted in maximum likelihood estimates age of 38 years; in lower likelihood estimates age of 29 and in upper likelihood estimates age of 53 years. The estimated body height was around 169 cm.

The individual has the usual diseases such as caries, calculus, parodontopathies on periodontium and light to medium osteoarthritis on postcranial skeleton. However, several fight injuries on the skull are remarkably.

A healed or longer survived head injury should be mentioned, located on the left-sided frontal bone between the linea temporalis and the Ala major of the left sphenoid (temple area) (Fig. 2 red box, Fig. 3). It is characterized by an approximately 1 cm long, 3-5 mm wide and 5 mm deep, arc-shaped groove, surrounded by several bone callus (Fig.3), providing the impression of a planar depression. The injury might be caused by a sharp arrow or spear. An almost identical injury exists at a female skull from the late Slavic burial Wusterhausen.

The second remarkable injury is situated on the left parietal. This is a 6 to 7 cm long, 1 to 3 mm wide and approximately 5 mm deep groove, which gets narrower and shallower from dorsal to ventral (Fig. 4 red box, Fig. 5). It also shows first signs of a healing process. A sharp weapon, for example a blade, might cause it. The subsequent dorsally, nearly circular and about 1 cm defect with damaged lamina externa is post mortem origin. Similar damages can be found on the left and right parietal.

Also there is approximately 1 x 1 cm flat dent (impression) on the left sided frontal in direct alignment to the blade injury. Its external surface (lamina externa) is intact and shows similar traces of de-

composition as the undamaged surface of the skull has (Fig. 4 blue box, Fig. 6). The impression could be the result of blunt force. An examination of the lamina interna, that could provide more answers, was not possible due to the otherwise intact skull.

The late-adult sword-wearer is characterized by strong enthesopathies on both femora (Fig. 7) and ossa coxae (Fig. 8), which are interpreted in the literature as an activity marker for "horseback-riding" syndrome".

Furthermore, first traces of a double-sided Poirier's facet are recognizable. It is remarkable in this context that there are two left rib fractures from the middle chest area. Whether a fracture of the left ulna and the left radius is present can be assessed only after an investigation of the block (sword plus upper left limb).

Discussion and conclusion

In spring 2013 nine other individuals could be recovered in close proximity to grave 1. One of them (grave 5) could be referred also as an "elite burial" because it was equipped with a ferrous metal bowl. The Sword and any further burial objective were missing due to robbery. A young adult woman from grave 7 stands out because of high disease stress and workload, through her body shape and abnormal orientation in the grave.

We summarize with this small part of a large cemetery burials with a unique combination of rich and extraordinary burial objects and the remarkable palaeopathological features, defining its archaeological value. Against this background the crisis-ridden circumstances at that time reflected the highly dangerous living conditions. Further studies on the provenance and relationship would be particularly desirable. A preliminary report concerning this elite grave from Stolpe is in press.



Fig. 1: Stolpe burial 1 with sword and ferrous metal bowl.

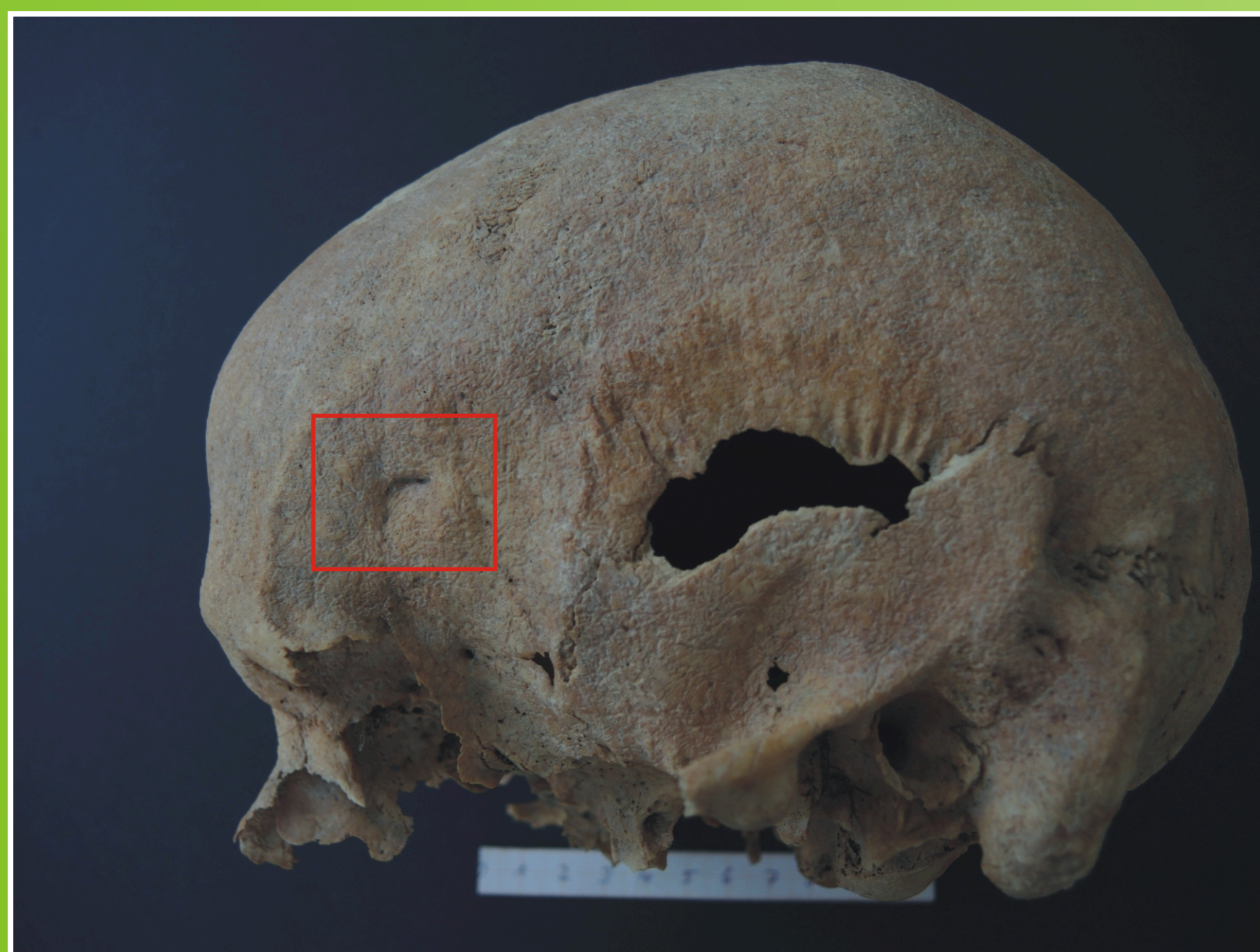

Fig. 2: Stolpe burial 1. Skull with healed injury might be caused by a sharp arrow or spear.



Fig. 3: Stolpe burial 1. Detail from fig. 2.



Fig. 4: Stolpe burial 1. Second injury might be caused by a sharp weapon e.g. a blade (red box) and the impression (blue box).




Fig. 5: Stolpe burial 1. Detail from fig. 4 red box.



Fig. 6: Stolpe burial 1. Detail from fig. 4 blue box.

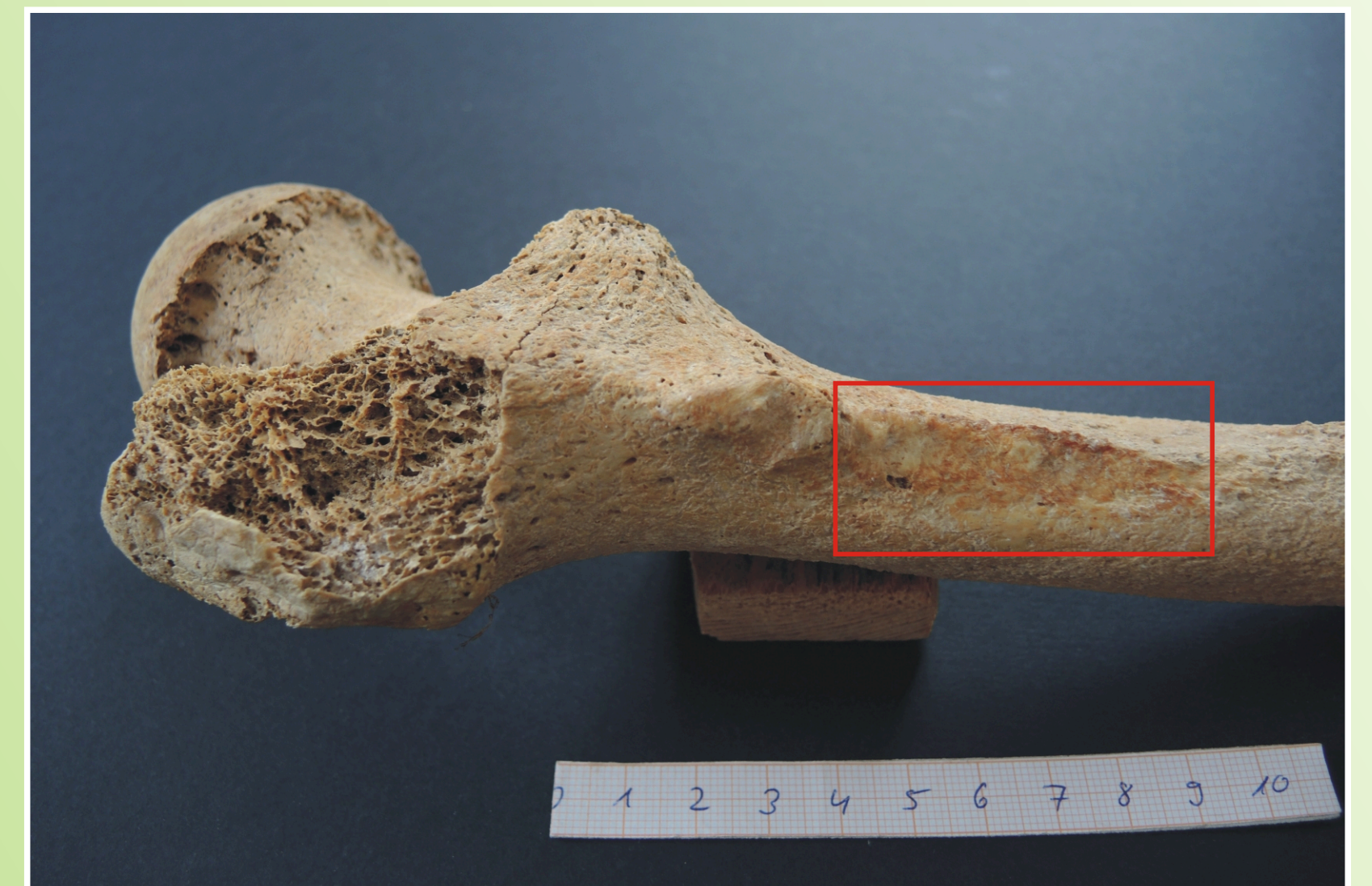

Fig. 7: Stolpe burial 1. Left femora with insertion of the M. gluteus maximus (red box).




Fig. 8: Stolpe burial 1. Left hip with origins of the M. gluteus maximus (red box) and M. gluteus medius (blue box).

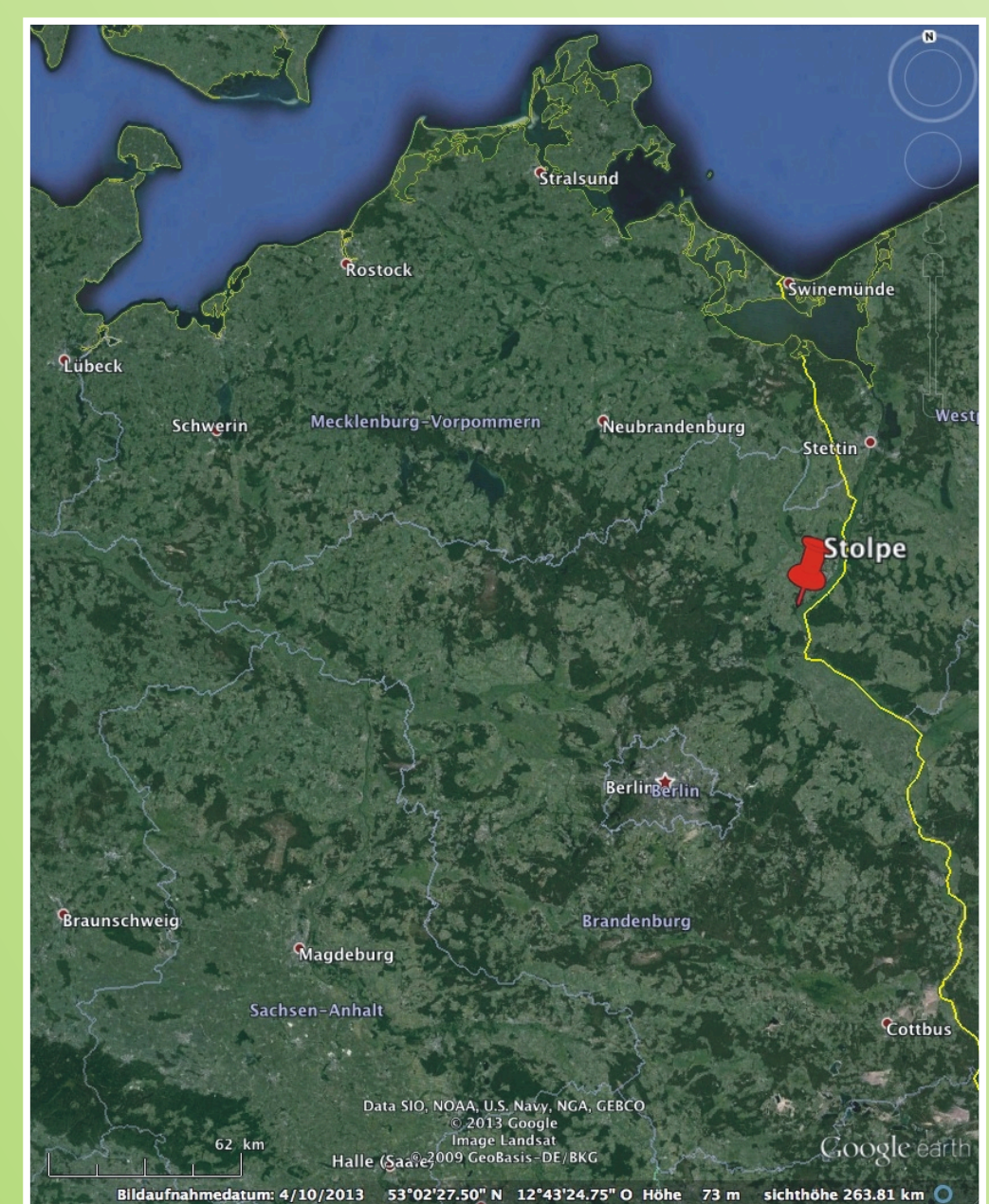


Fig. 9: Location of Stolpe (red pin).

¹abp Anthropologische Bestimmungen und Projektbetreuung

³Brandenburgisches Landesamt für Denkmalpflege und
Archäologisches Landesmuseum

²Georg-August-Universität Göttingen, Seminar für Ur- und
Frühgeschichte

⁴AAB Ausgrabungen und Bauprojektbetreuung